



Reason Stent, Ulceration

Outcome disease mild, disease moderate, Occlusion, Calcified, Stenosis Moderate, Calf vessel disease

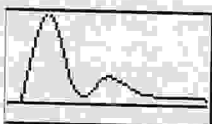Right

128

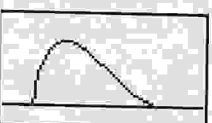1.00



Good



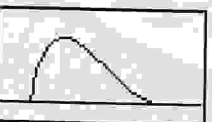Good



Slightly Reduced

102

0.80



Slightly Reduced

Brachial

Common Femoral

High Thigh

Low Thigh

Popliteal

High Calf

Peroneal

Anterior Tibial

Posterior Tibial

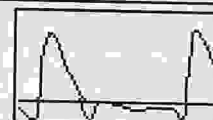Dorsalis Pedis

Toe Pressure

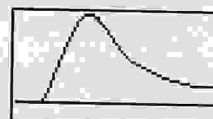
Post Exercise

Left


Good



Good



Absent



Absent at ankle



Notes

BILATERAL LOWER LIMB ARTERIAL DUPLEX SCAN

previous bilateral kissing iliac stents

all measurements proximal to the medial malleolus unless otherwise stated

AORTA - Abdominal aorta is widely patent with slightly reduced biphasic waveforms and PSV 61cm/s. The abdominal aorta appears of normal calibre (maximum AP = 1.1cm), with no evidence of focal dilatation or aneurysm identified.

Assessed by Rae Larmour

Printed on 17/06/2022 at 2:43 pm

Checked by



RIGHT

CIA (stent) - Appears patent with good bi/triphasic waveforms and PSV 188-162cm/s

EIA (stent) - Patent with good triphasic waveforms and PSV 84cm/s.

CFA - Patent with mild disease, good triphasic waveforms and PSV 104cm/s.

PFA (origin) - Patent with mild disease, good biphasic waveforms and PSV 188cm/s.

SFA - Patent along length and through the adductor canal with diffuse mild and calcified disease, becoming diffuse moderate and calcified distally. Good triphasic waveforms and PSV 142-133cm/s.

POPA - Good hyperaemic mono/triphasic waveforms and PSV 115-58cm/s.

TPT - Poorly visualised but where seen ?2 vessel run-off identified and moderate disease.

ATA - Moderate disease proximally, good hyperaemic monophasic waveforms and PSV 183cm/s. Mild disease in the mid-distal vessel, slightly reduced monophasic waveforms and PSV 79cm/s.

PTA - Unable to identify proximally ?patency; likely occluded. Flow appears to reform in the mid calf at ~16cm with slightly reduced monophasic waveforms and PSV 22cm/s.

LEFT

CIA (stent) - Patent proximally with good biphasic waveforms and PSV 94cm/s. Moderate disease in the mid-distal vessel for ~2.4cm with PSV increasing to 350cm/s.

EIA (stent) - Patent with good biphasic waveforms and PSV 82cm/s.

CFA - Patent with moderate and calcified disease, good biphasic waveforms and PSV 89cm/s.

PFA (origin) - Patent with mild and calcified disease, good biphasic waveforms and PSV 154cm/s.

SFA - Patent along length and through adductor canal with diffuse mild and calcified disease, good biphasic waveforms and PSV 91-81cm/s. Moderate stenosis at ~72cm for ~0.9cm with PSV increasing from 65cm/s to 251cm/s.

POPA - Patent with mild disease proximally, good monophasic waveforms and PSV 88cm/s becoming moderate and calcified in the mid-distal vessel, slightly reduced monophasic waveforms and PSV 63cm/s.

TPT - Patent but poorly visualised, moderate disease.

ATA - Appears occluded from the proximal calf to the ankle. No flow identified within vessel lumen and veins clearly visualised.

PTA - Appears occluded in the proximal calf with no flow identified within vessel lumen. Flow appears to reform in the mid calf for ~10cm before the vessel occludes again and remains so to the ankle.

ABPI - Right resting ABPI is just within normal limits. Exercise test attempted, however, patient unable to adequately perform due to position of ulcer. Unable to obtain left resting ABPI due to absence of signal at ankles.

